


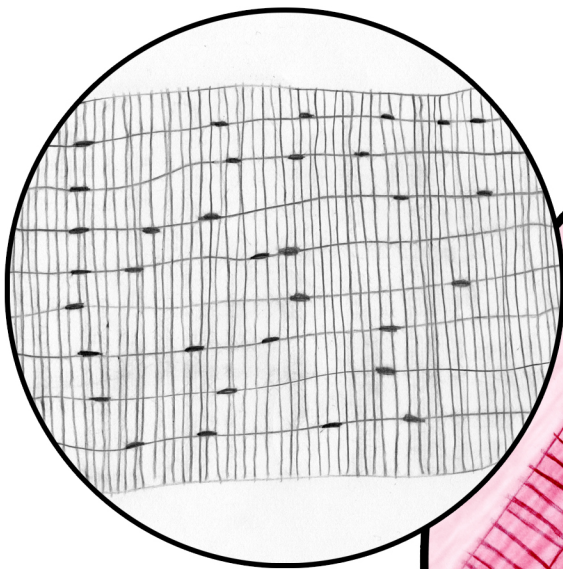
HISTOLOGY: Muscle Tissues–Skeletal

Locations: skeletal muscles are attached to the skeleton, or some may say “outside” the skeleton.

Functions: voluntary movement/control, locomotion, facial expressions, manipulation of environment.

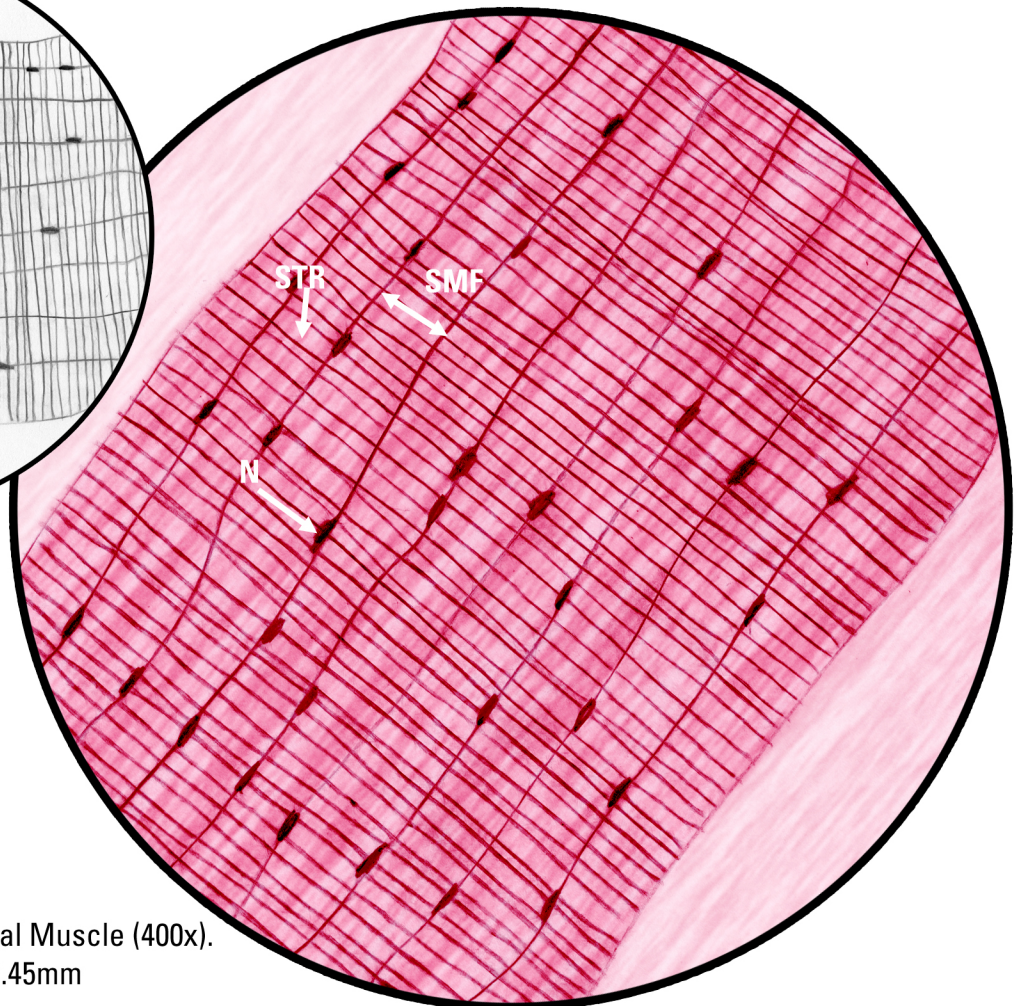


Skeletal Muscle (100x). FOV=1.80mm Microscope Photography: Shirley Chung



Key

N, Nucleus
SMF, Skeletal Muscle Fiber Cell
STR, Striations from M-Lines
FOV, Field of View



Skeletal Muscle (400x).
FOV=0.45mm