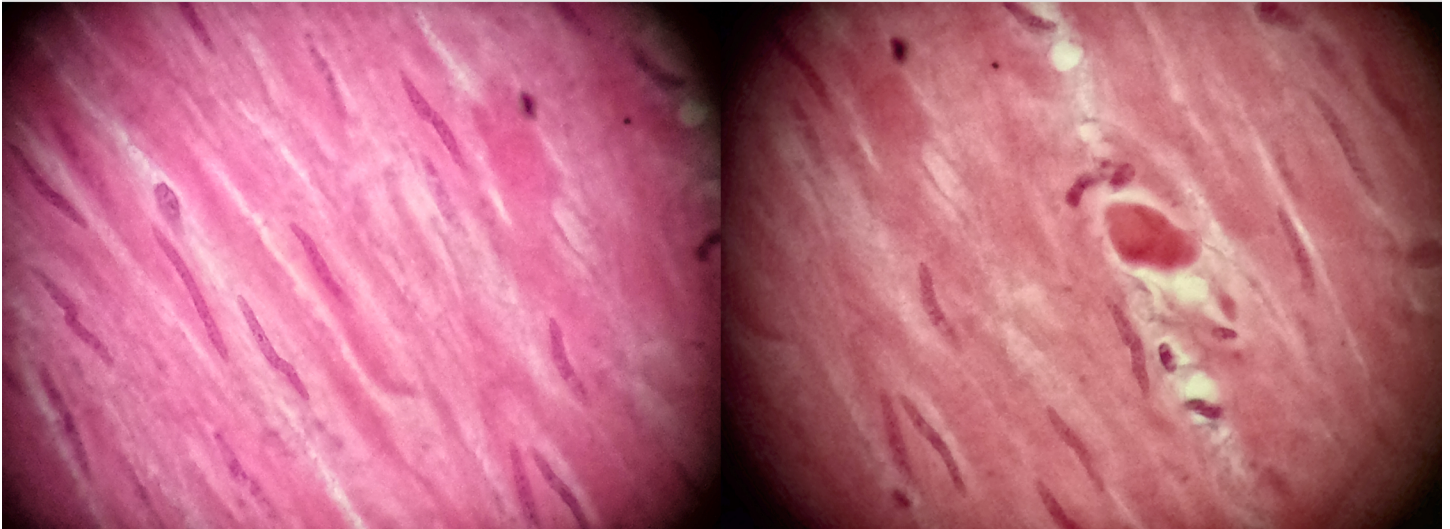


## HISTOLOGY: Muscle Tissues–Smooth

Locations: in the walls of hollow organs/"tubes", vessels, small/large intestine.

Functions: involuntary movement/control; peristalsis, segmentation.



Smooth Muscle (400x). FOV=0.45mm Microscope Photography: Shirley Chung

