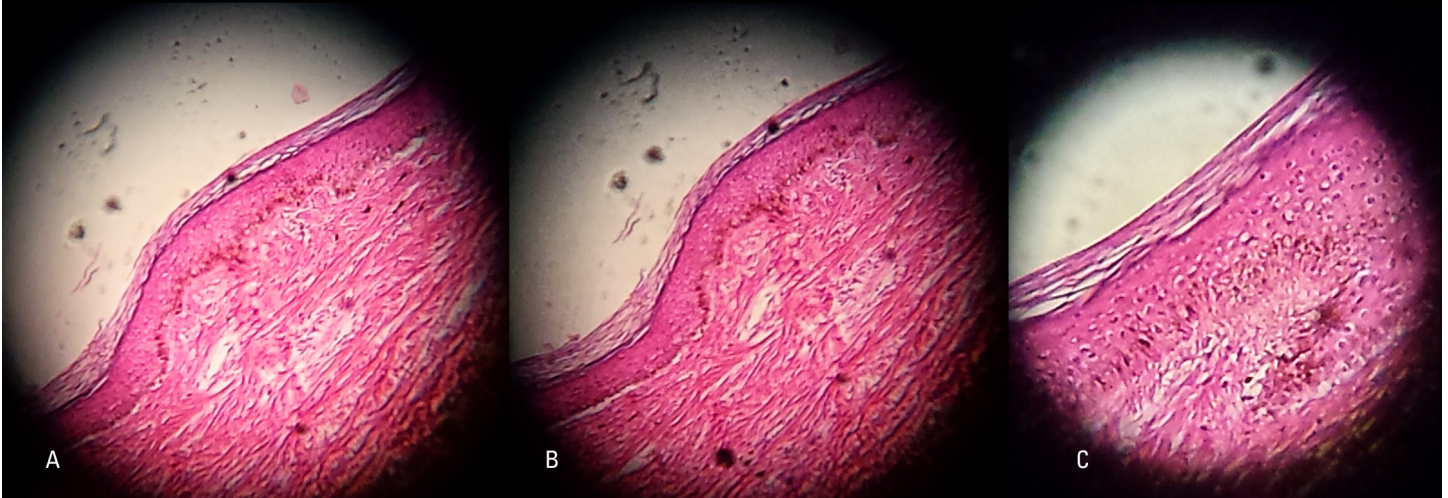


HISTOLOGY: Integumentary System—Pigmented Skin (100x)



Pigmented Skin A) at 100x; B) at 100x; C) at 400x. Microscope Photography: Shirley Chung

