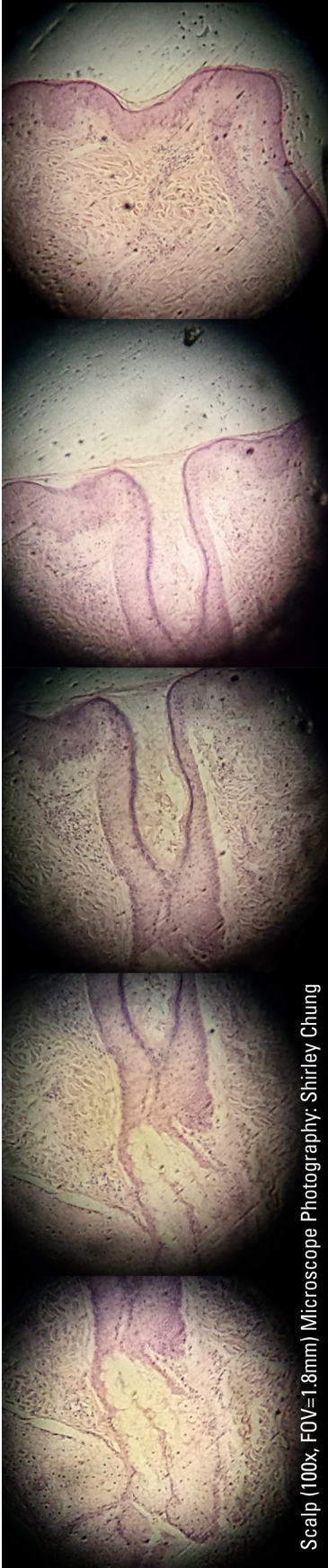
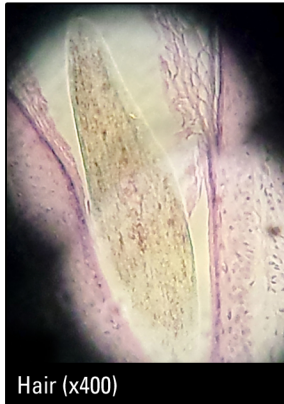


**HISTOLOGY: Integumentary System—Scalp (100x)**



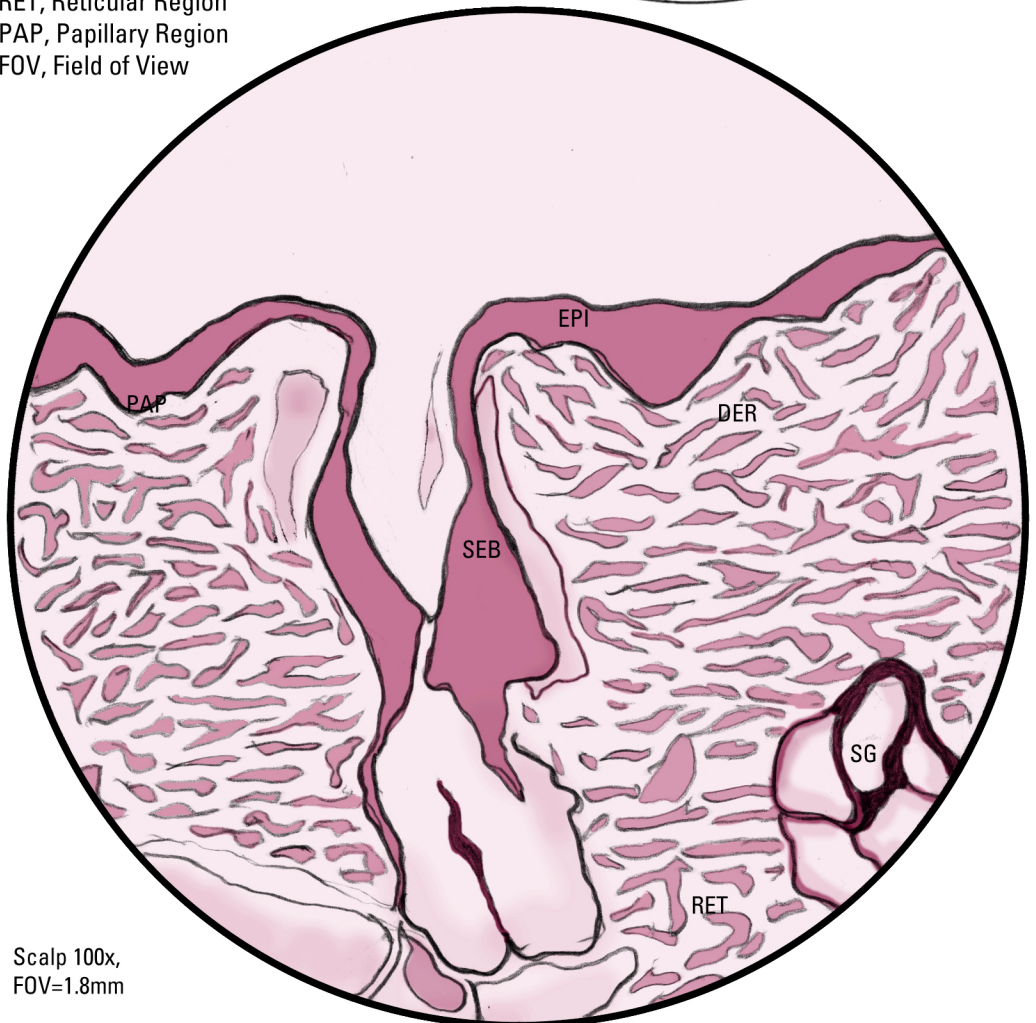
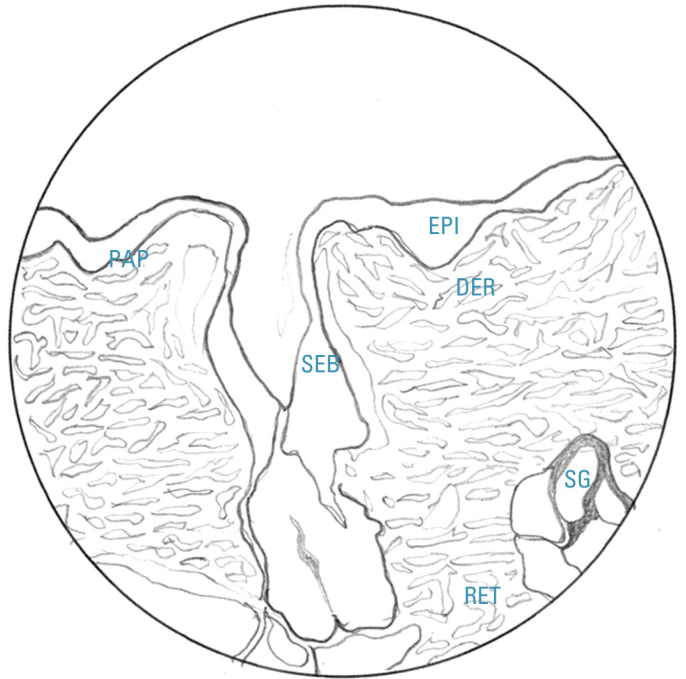
Scalp (100x, FOV=1.8mm) Microscope Photography: Shirley Chung



Hair (x400)

**Key**

- SEB, Sebaceous Glands
- SG, Sweat Glands
- EPI, Epidermis
- DER, Dermis
- RET, Reticular Region
- PAP, Papillary Region
- FOV, Field of View



Scalp 100x,  
 FOV=1.8mm