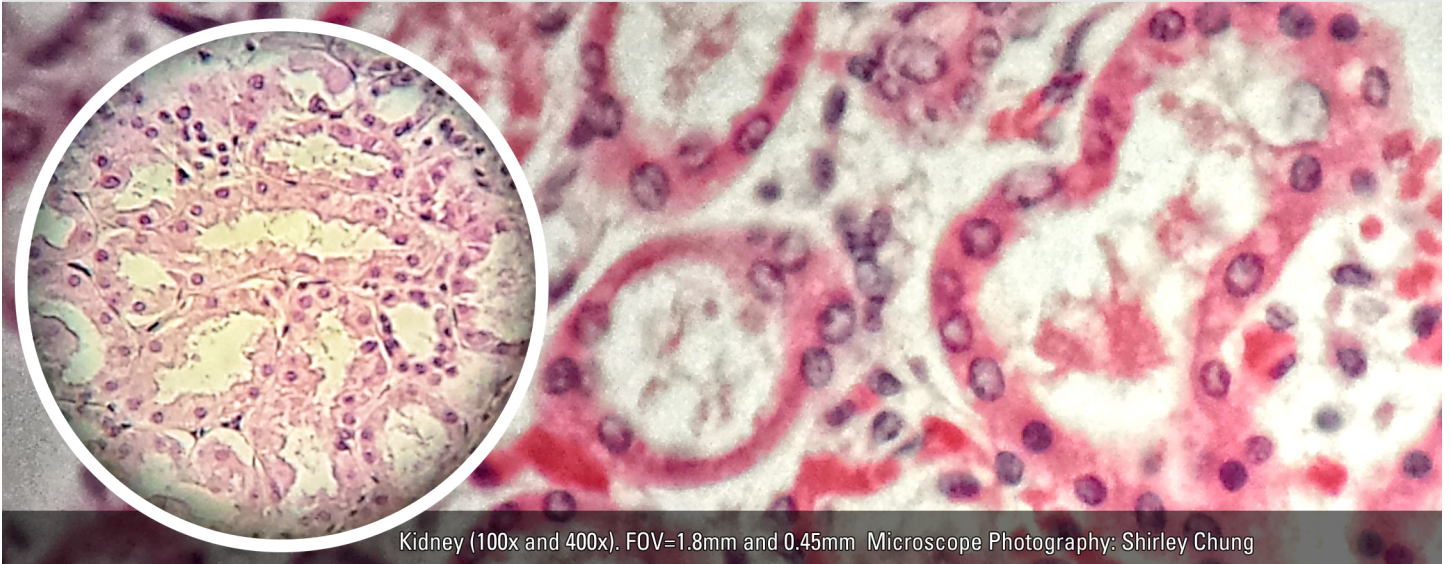


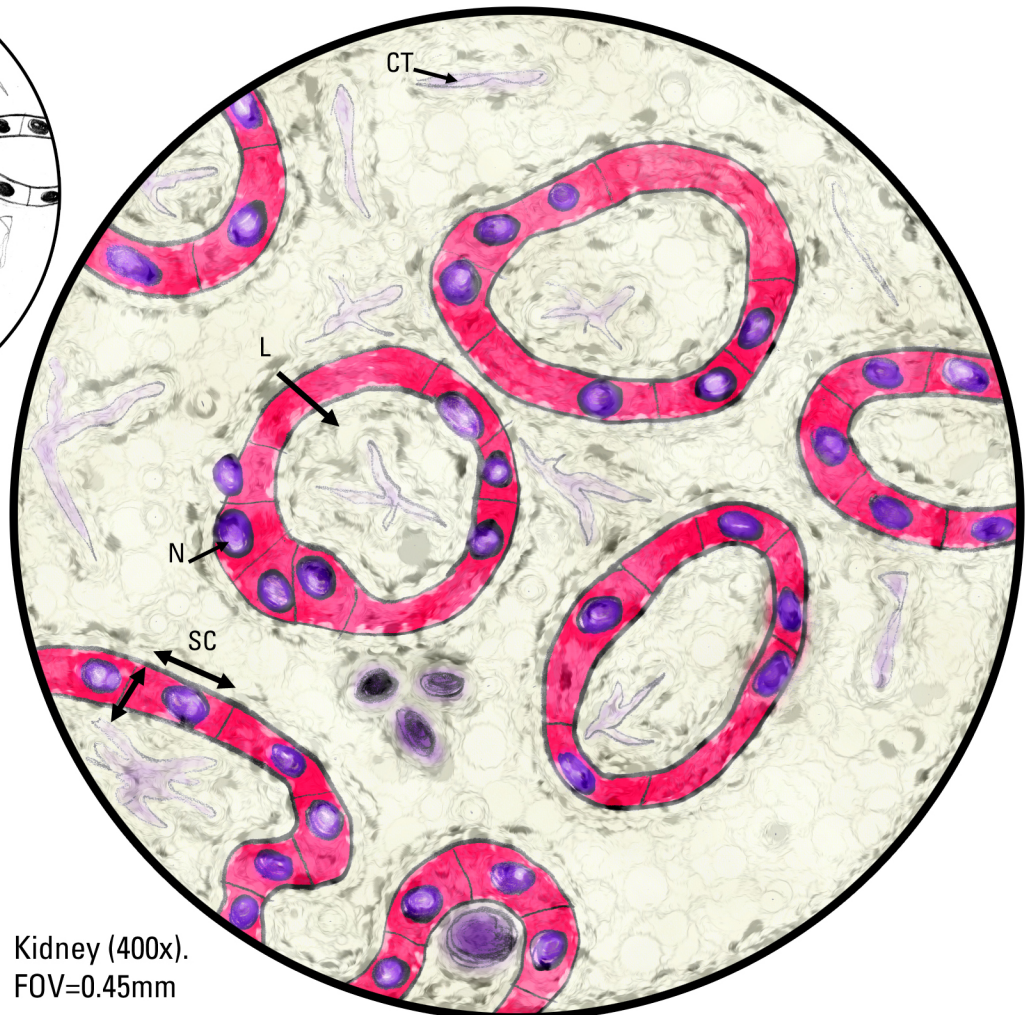
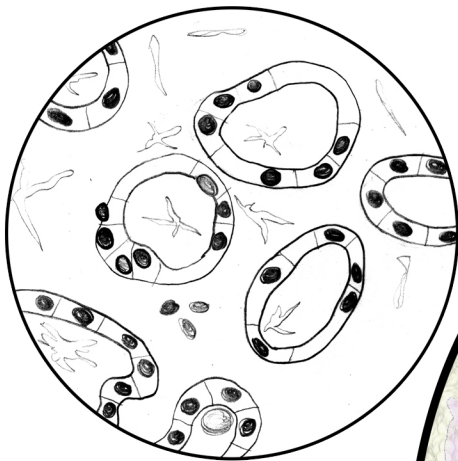
HISTOLOGY: Epithelial Tissues—Simple Cuboidal (Kidney)

Locations: kidney tubules, ovary surface, ducts/secretory parts of small glands.

Functions: secretion, absorption.



Kidney (100x and 400x). FOV=1.8mm and 0.45mm Microscope Photography: Shirley Chung



Key

- L, Lumen
- CT, Connective Tissue
- SC, Simple Cuboidal
- N, Nucleus
- FOV, Field of View

Kidney (400x).
FOV=0.45mm