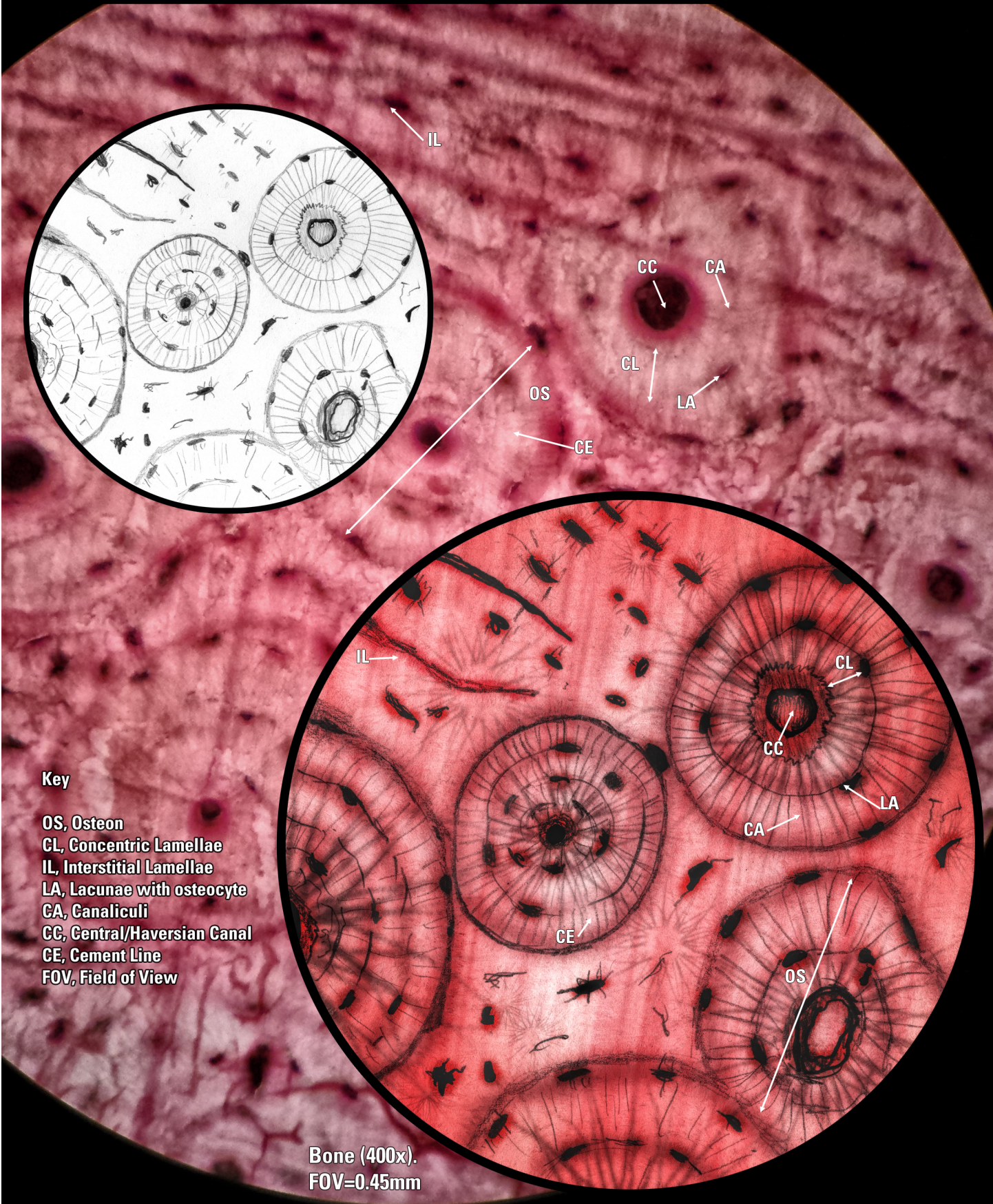


HISTOLOGY: Bone Tissue (400x)



Key

- OS, Osteon
- CL, Concentric Lamellae
- IL, Interstitial Lamellae
- LA, Lacunae with osteocyte
- CA, Canaliculi
- CC, Central/Haversian Canal
- CE, Cement Line
- FOV, Field of View

Bone (400x).
FOV=0.45mm