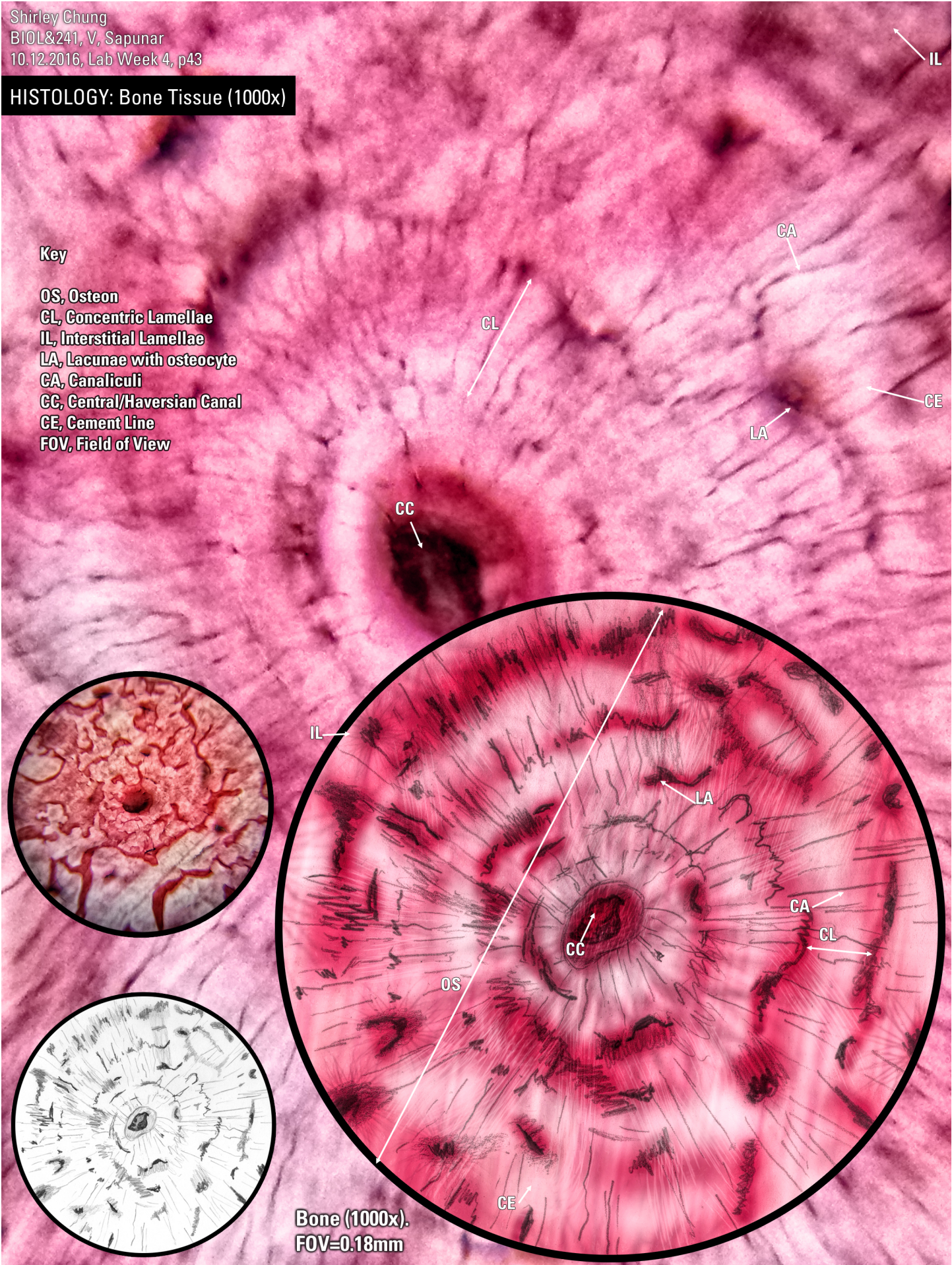


HISTOLOGY: Bone Tissue (1000x)

Key

- OS, Osteon
- CL, Concentric Lamellae
- IL, Interstitial Lamellae
- LA, Lacunae with osteocyte
- CA, Canaliculi
- CC, Central/Haversian Canal
- CE, Cement Line
- FOV, Field of View



Bone (1000x).
FOV=0.18mm